

HEADACHES IN THE PEDIATRIC EMERGENCY ROOM

July 25, 2009

Medical City Dallas

Dallas, Texas

Steven L. Linder, M.D.

Dallas Pediatric Neurology Associates

Dallas, Texas

CASE HISTORY

Ten year old male with history of migraine since 7 years of age, well controlled on cyproheptadine daily with the use of Excedrin for acute headache. Over the past month the headaches have become more frequent and severe. The patient was hit in the head with a baseball bat 4 days prior to admission with a constant headache since that time. Seen in the emergency room with a non-focal examination, weight 40 kg. CT was normal. Was give sumatriptan 6-mg SQ with an increase in headache pain. Was then given promethazine and meperidine and he went to sleep.

The next day the headache returned and he was seen in the ER. Comprehensive headache examination showed bilateral supraorbital nerve tenderness, bilateral temporalis tenderness as well as tenderness in the neck. He was treated with IV metaclopramide 10-mg followed by dihydroergotamine (DHE) 45-0.5 mg IV. He had exacerbation of his headache plus became extremely restless. He was admitted to the hospital for further evaluation.

QUESTIONS

1. Why did cyproheptadine become ineffective?
2. Why did Excedrin become ineffective?
3. What is an appropriate dose of subcutaneous sumatriptan for a 10-year-old weighing 40 kg?
4. What is an appropriate dose of DHE?
5. Why did the patient's headache increase after DHE?
6. Why did the patient develop agitation and restlessness after IV metaclopramide?
7. How would you treat this patient?

Which Kids Will Respond to Standard Therapies and Which Kids Will Not?

If the general physical examination is normal and there is no apparent illness:

- The physician must feel comfortable with basic neurologic examination
- Comprehensive headache examination



COMPREHENSIVE HEADACHE EXAMINATION

- Cervical spine examination
- Skull- palpation of bones, muscles and listen for bruits
- Ears- external auditory meatus occlusion and motion
- Temporomandibular joint- palpation, range of motion
- Nerves – palpation of: supraorbital, trochlear and occipital nerves as well as cranial nerves IX-XII.
- Eyes- palpation and inspection
- Sinuses- modified Muller's maneuver
- Evaluation for increased intracranial pressure
- Teeth- inspection, percussion, palpation
- Carotid arteries- listen for bruits - palpate

Clinical Pearls for Central Allodynia

1. Tenderness over supraorbital nerves.
2. Cervical tenderness (C3-C6), more prominent on the left.

Recommendations

1. Allodynic-free patients may do well with OTC's or combination of OTC's
2. Allodynic-free patients usually do well with triptans
3. If treat late, triptans may be of partial benefit
4. Treat before allodynia develops

Case History

- Three year old with headache and neck pain
- Evaluation in the emergency room should include
 1. C-spine films
 2. MRI – not CT

Name: DAMS, JACKSON
ID: 1249528
DoB: 8/22/2000
Date:
Time:
No.: 14
Pat C:
x 1.3

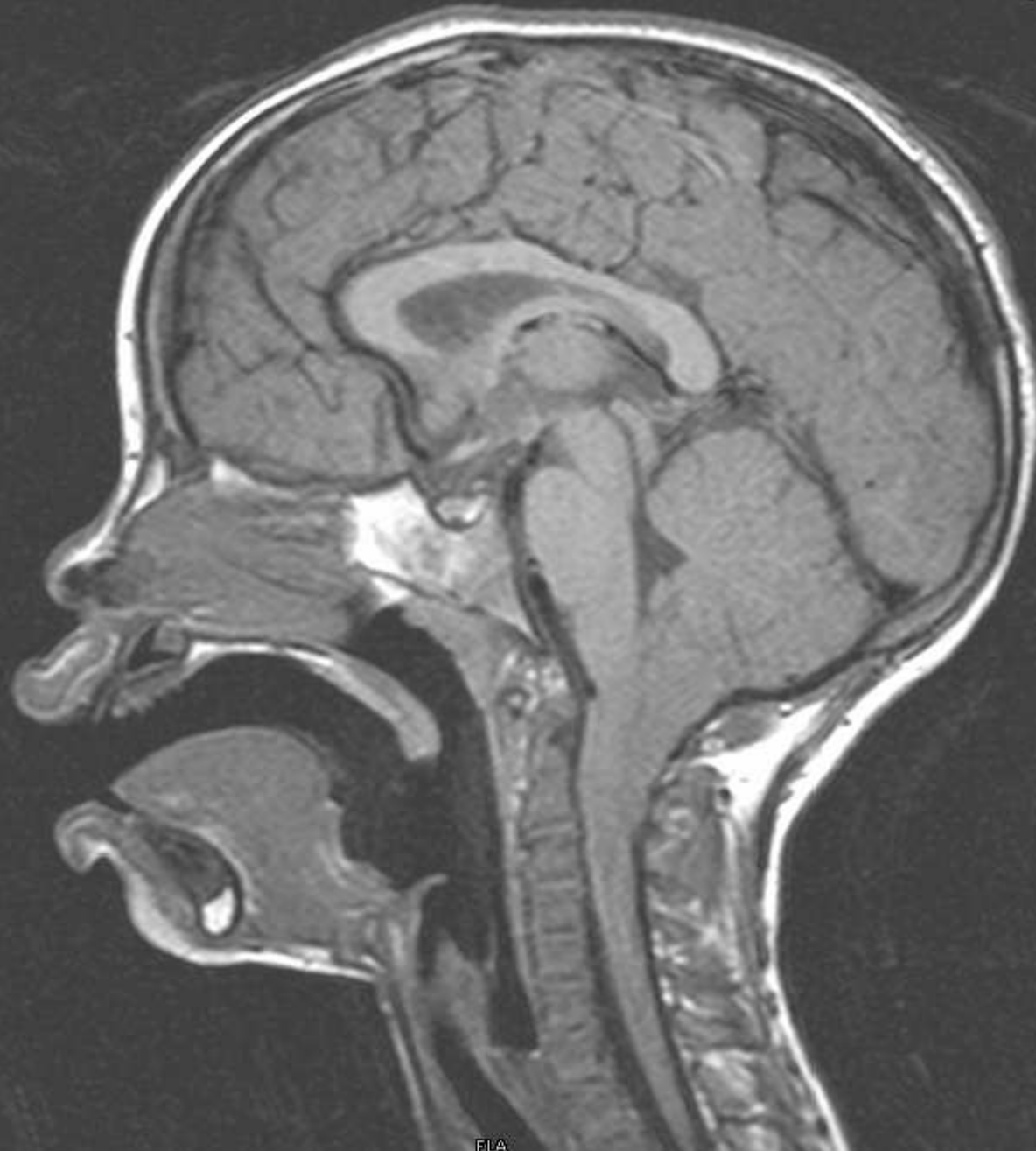
HRP

Inst: CHILDRENS MEDICAL CENTER MR1

Model: Gyroscan Intera

Organ:

14



AR



TT:
TI:
TR: 425.00
TE: 13.50
Matrix:
SD:

FLA

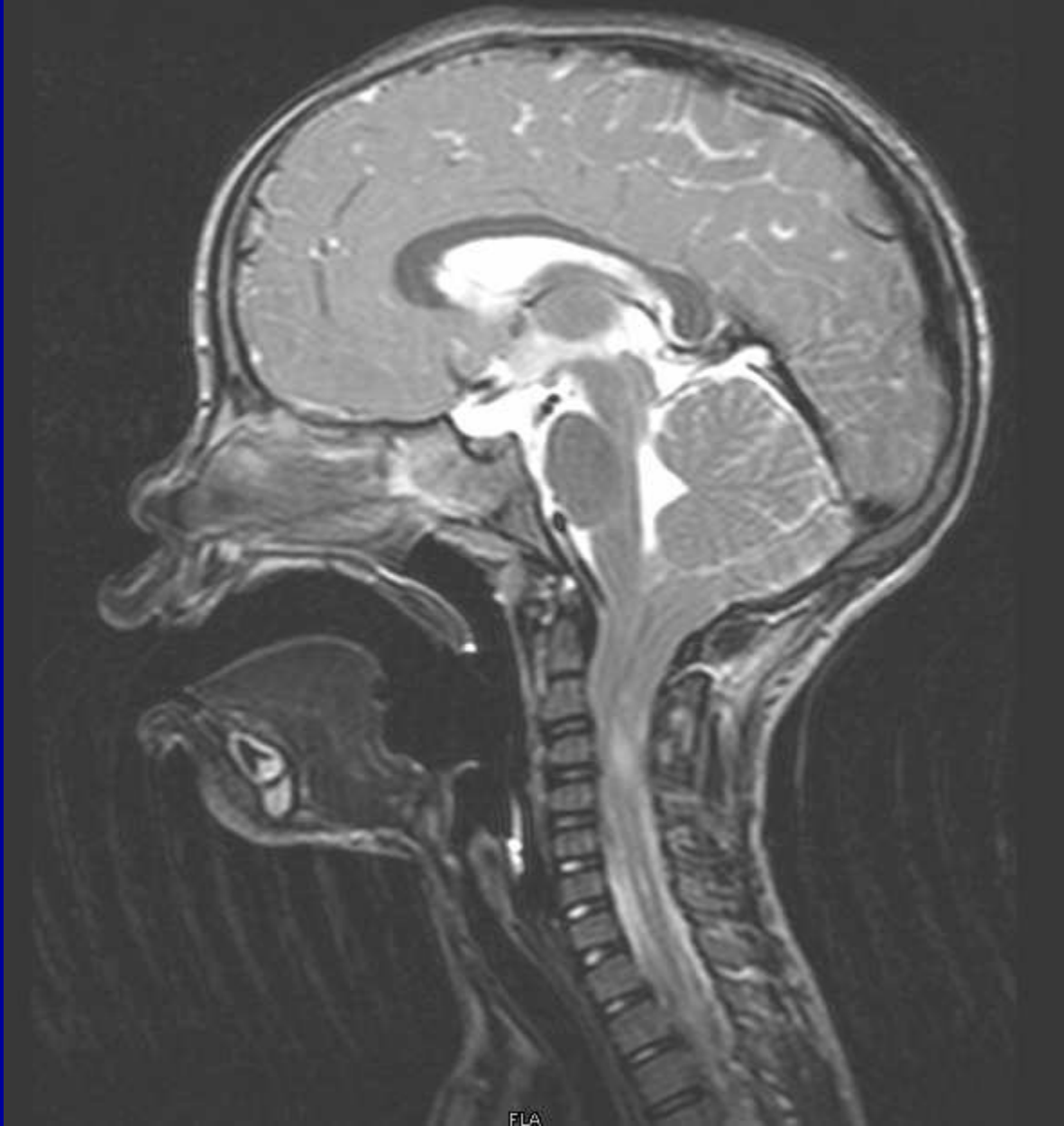
CM:
SL:
ST: 3.00
Angle: 90.00
FoV: 100.00
Im C:
W: 01847
C: 00488

KSON

HRP

Inst: CHILDRENS MEDICAL

Model: C



FLA

CHIARI MALFORMATION

COMPLICATIONS OF CHIARI MALFORMATION:

Cervical Syrinx

Sleep Apnea

COMPLICATIONS OF SURGERY

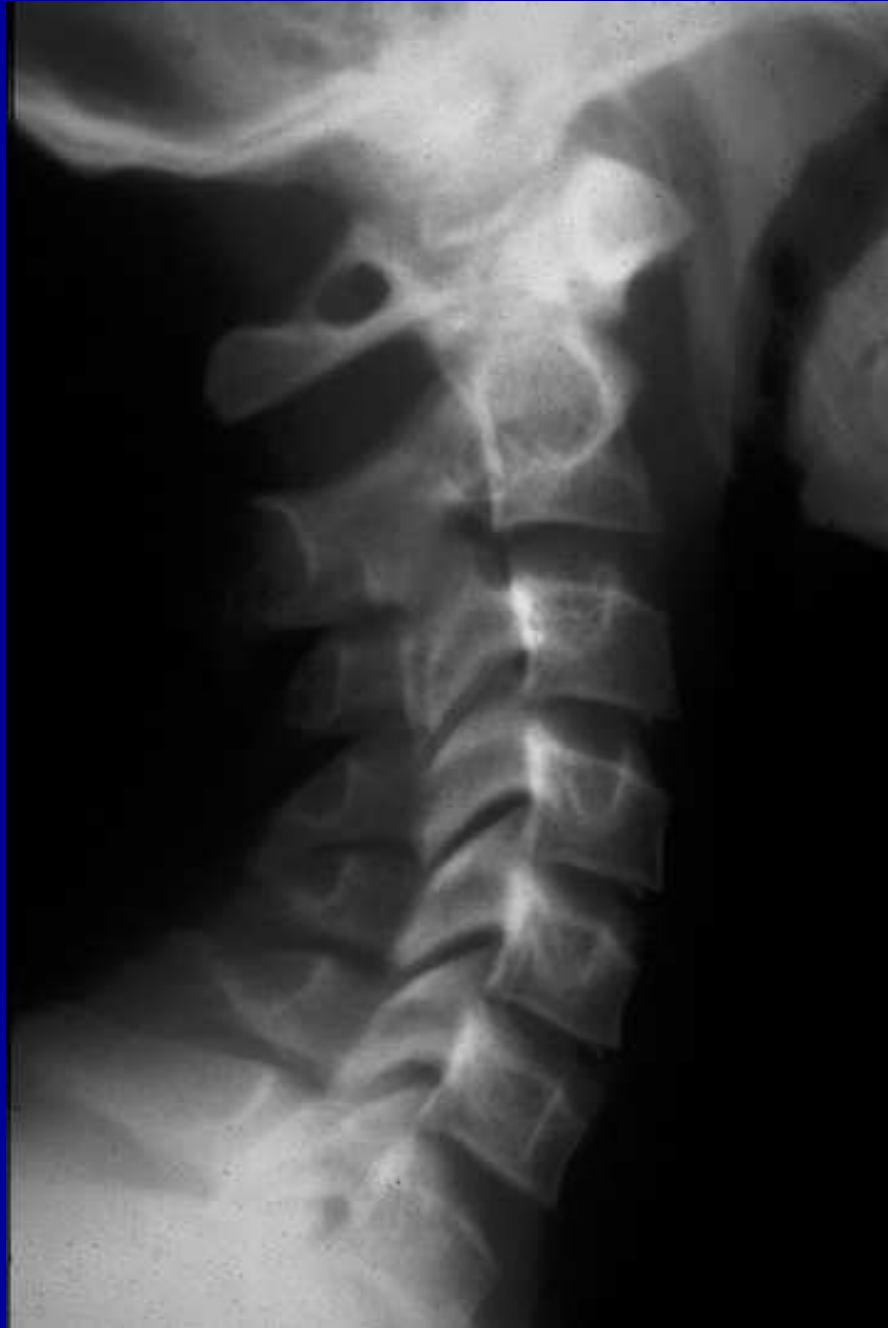Refractory Headache Syndrome

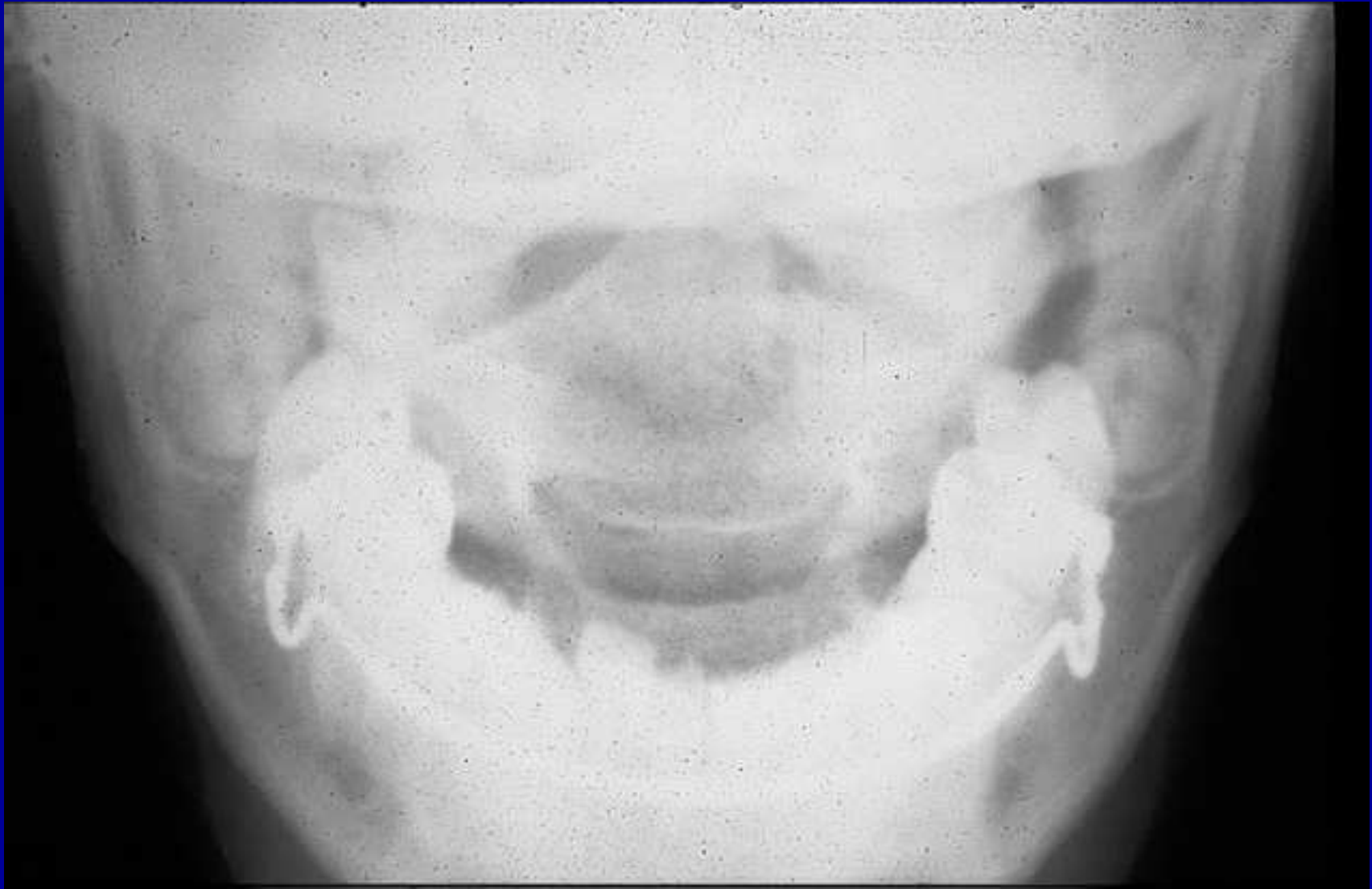Case History

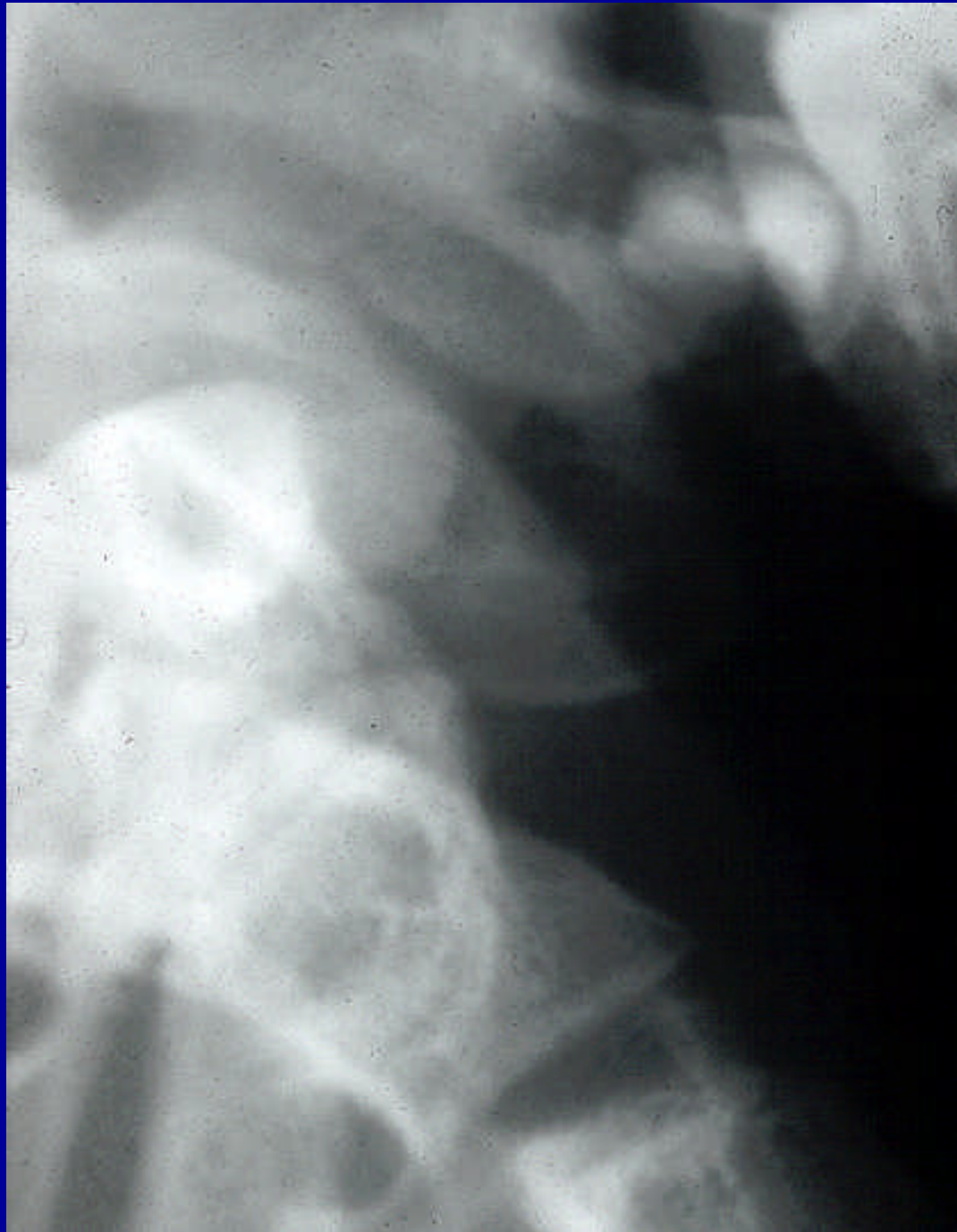
Eight year old male who presents with neck pain and associated headache which move to the frontal region at times the neck pain is associated with a tingling sensation in his neck.

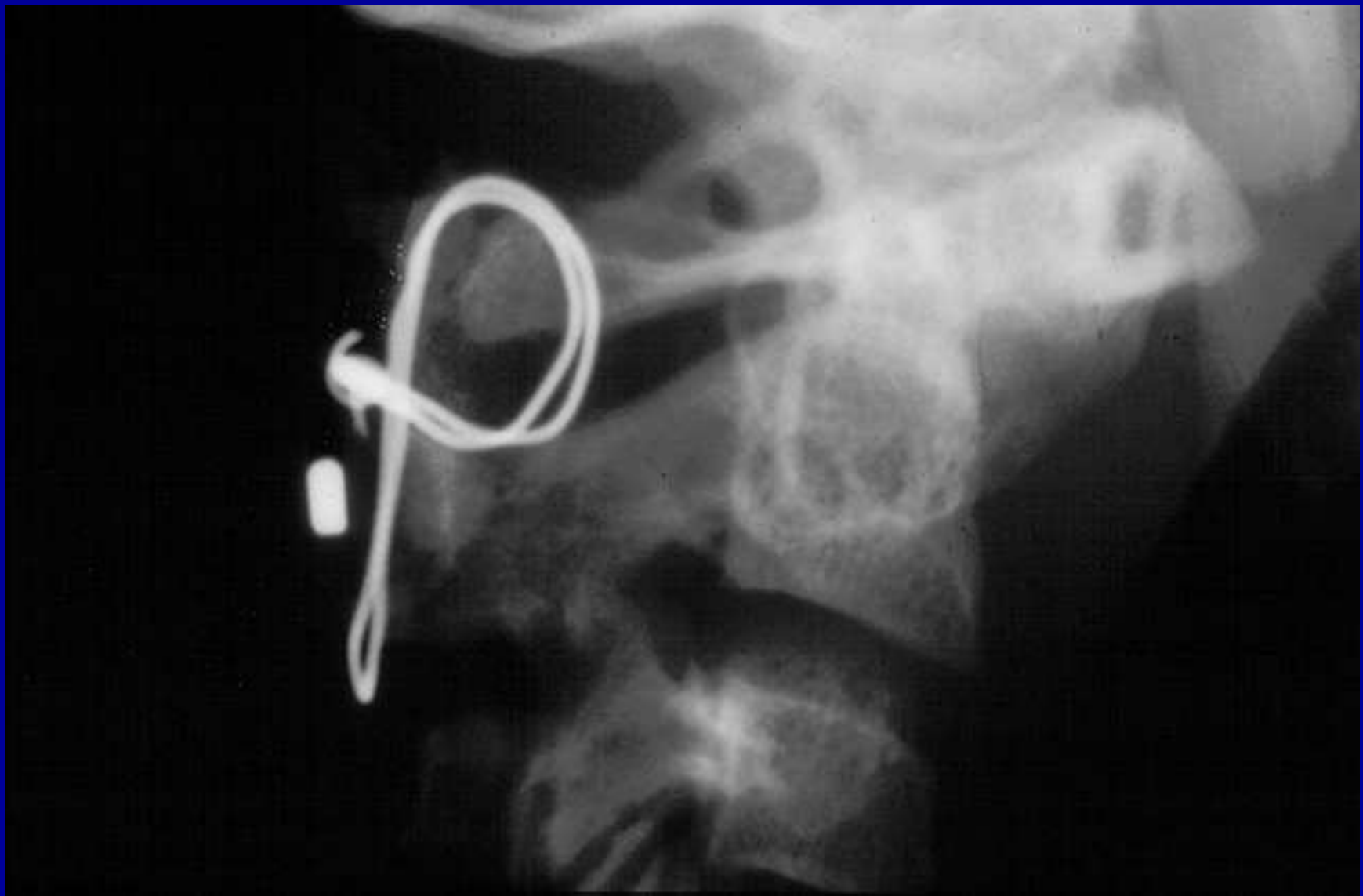Differential Diagnosis

- Arnold Chiari Malformation
- Dandy Walker Malformation
- Subluxation of C1 and C2
- Subluxation of the lateral atlantoaxial joint
- Conversion reaction as this does not fit any anatomical patterns









SNOOP

SNOOP: Red flags

1. Systemic symptoms
2. Neurological symptoms
3. Onset is abrupt
4. Onset is in older patient
5. Previous headache history is different

Headache Presenting to the ER

- Acute Headache Etiologies
 - Infection
 - Hemorrhagic SAH, intracranial
 - Migraine
 - Hypertension
 - Trauma
 - Substance abuse
 - Intoxications
 - Medications

Headache Presenting to the ER

- Chronic Progressive Headache
 - Hydrocephalus
 - Neoplasm
 - Abscess
 - Hematoma
 - Chronic infections
 - Pseudo tumor cerebri, aneurysm
 - Chiari malformation
 - Hypertension, Medications, Intoxications

Acute Headache in Children in the ER

Lewis

150 Children – Ages 2-18

1.	Upper respiratory Infection	39%
2.	Sinusitis	9%
3.	Strep throat	9%
4.	Migraine	18%
5.	Viral meningitis	9%
6.	Posterior fossa tumor	2.6%
7.	VP shunt malfunction	2%
8.	Intracranial hemorrhage	1.3%
9.	Undetermined	7%

Comment: Serious underlying CNS problems are uncommon and when present, are accompanied by multiple neurological signs.

PRACTICE PARAMETERS FOR CHILDREN AND ADOLESCENTS WITH RECURRENT HEADACHE

Lewis

- Neuroimaging on a routine basis is not indicated with recurrent headaches and a normal neurological examination
- Variables that suggestion space occupying lesions include:
 - 1. Headache less than a month
 - 2. Absence of family history of migraine
 - 3. Abnormal neurological findings
 - 4. Gait abnormalities
 - 5. Occurrence of seizures

EVALUATION IN THE EMERGENCY ROOM

If the general physical examination is normal and there is no apparent illness:

- The physician must feel comfortable with basic neurologic examination
- Comprehensive headache examination

General Principles of Management

1. Establish Diagnosis
2. Educate migraine sufferers
3. Establish realistic patient expectations
4. Identify life style changes

Sleep

Caffeine/diet

Comorbid conditions

Acute Treatment

1. Treat rapidly
2. Restore functional ability
3. Minimize use of necessary medicines
4. Consider self administered rescue medicines for the future
5. Use migraine specific agents: i.e. triptans and DHE
6. Guard against medication overuse headache
7. Consider starting daily preventative
8. DHE with D5 & $\frac{1}{2}$ normal saline at 20-mg/kg/100 given over 2-4 hours

Adult Treatment Regimen in the Emergency Room

- I. Ketorolac 30-mg IM vs. meperidine 75-mg for severe migraine

Larkin

At one hour:

1. Ketorolac less effective in reducing headache pain and improving disability
2. Ketorolac less effective for reducing nausea, photophobia, phonophobia and need for rescue medications
3. Sustained relief (24 h) 13% vs 44% with meperidine

However. . . .

Adverse events to meperidine:

1. sedation
2. nausea
3. respiratory depression
4. urinary retention
5. hypotension
6. possible addiction

II. Dihydroergotamine/hydroxyzine IM vs. Meperidine/hydroxyzine IM

Carleton, 1998

Both results comparable but use of dihydroergotamine avoided problems with opioid analgesia including dizziness and sedation

III. Comparison dihydroergotamine/metoclopramide vs. meperidine with promethazine

Scherl

Meperidine 75-mg IM
Promethazine 25-mg IM

Dihydroergotamine 0.5-mg IV
Metoclopramide 10-mg IV

After one hour pain relief similar but more adverse events with use of meperidine

Use of Narcotic Analgesics in the Emergency Department Treatment of Migraine Headache Colman, 2004

Practice Guidelines Recommended:

Metoclopramide

Sumatriptan

Dihydroergotamine

Chlorpromazine

Prochlorperazine

Narcotic analgesics are recommended for rescue
medicines or as a “last resort”

Five Canadian hospital studies with 59.6% received narcotics as first- line treatment (range 35% to 78%) with meperidine as the medicine of choice in 78%.

In this study it is important to note that the use of narcotics depended on each hospital's protocol.

If narcotics used as first-line treatment patients are:

- a. Less likely to have IV medicine and less likely to received bolus of IV medicine
- b. More likely to receive an anti-emetic
- c. Have a shorter time in the emergency department
- d. Significantly more likely to return to the same ER within 7 days
- e. Narcotic abuse in 7% to 19%

Meperidine binds to opiate receptors in the CNS causing inhibition of ascending pain pathways, alternating the perception of the response to pain, but does not influence receptors of current pathophysiology of migraine

Conclusion:

Acute migraine management in the emergency department does not meet the current guidelines established by the American Academy of Neurology

But, What About My Headaches?



Emergency Treatments

Prochlorperazine in Children

The effectiveness and tolerability of prochlorperazine in aborting intractable migraine in children

Kabbouche & al.: Pediatrics April 2001

At 1 hour: 75% improvement with 50% headache free

At 3 hours: 95% improvement with 60% headache free

Emergency Treatments

Prochlorperazine vs. Metoclopramide

Randomized prospective double-blind, placebo-controlled study:

Coppola & al.: Ann Emerg Med, April 1996

	Prochlorperazine	Metoclopramide	Placebo
Pain improvement	82%	46%	29%

Emergency Treatments

Prochlorperazine vs. Ketorolac

Perspective double-blind study (Pediatric migraine)

Brousseau & al.: Ann Emerg Med, Feb 2004

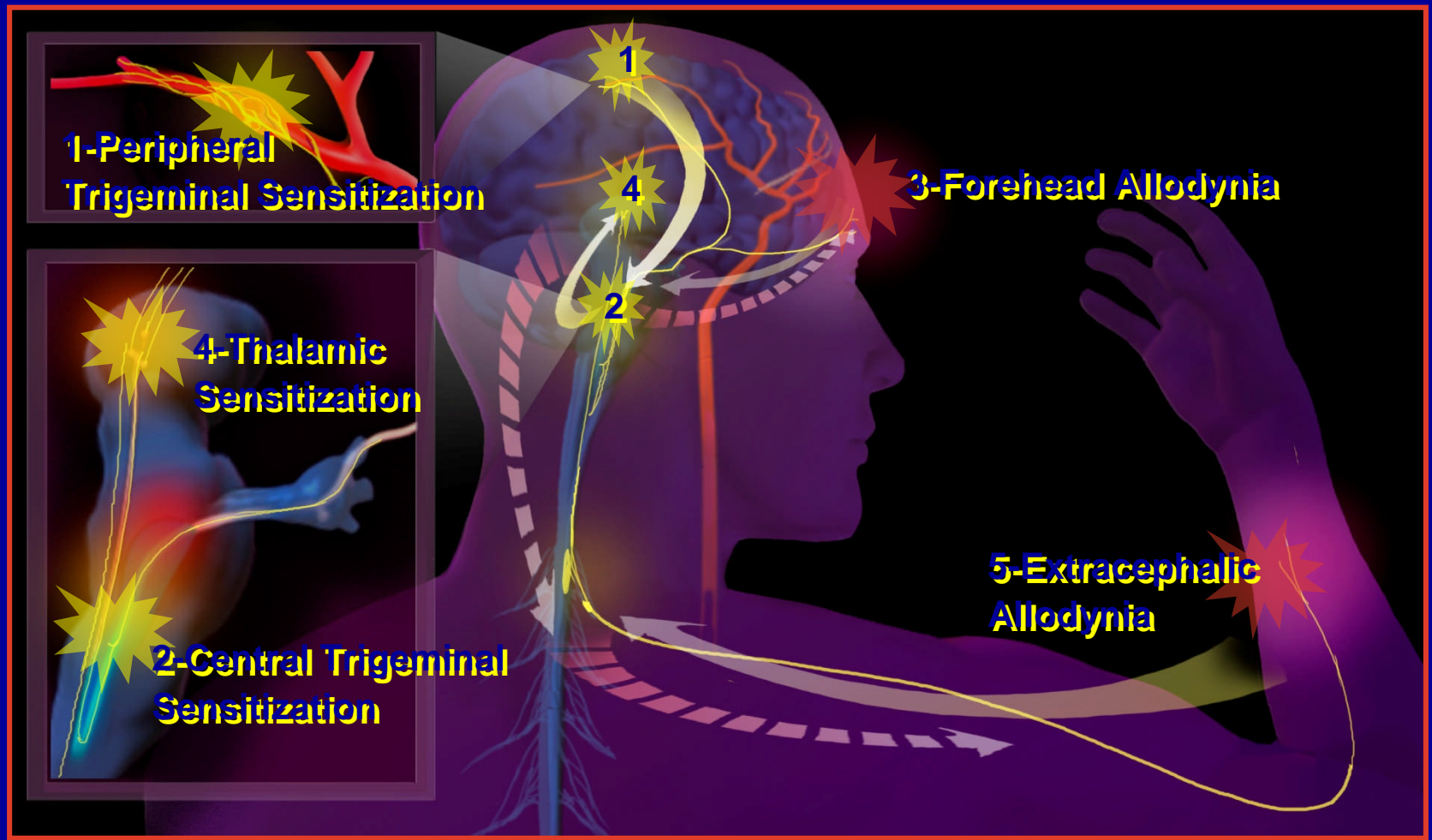
At 1 Hour:

- 84.8% responded to prochlorperazine
- 55.2% Ketorolac
- 93% response when treatments were combined
- 30% recurrence in 24 hours

Why Are These Medicines Not Working?

- Utilizing these medications we are not treating the basic pathophysiology of migraine
- We need to understand what is happening in the child's brain during migraine

CUTANEOUS ALLODYNIA

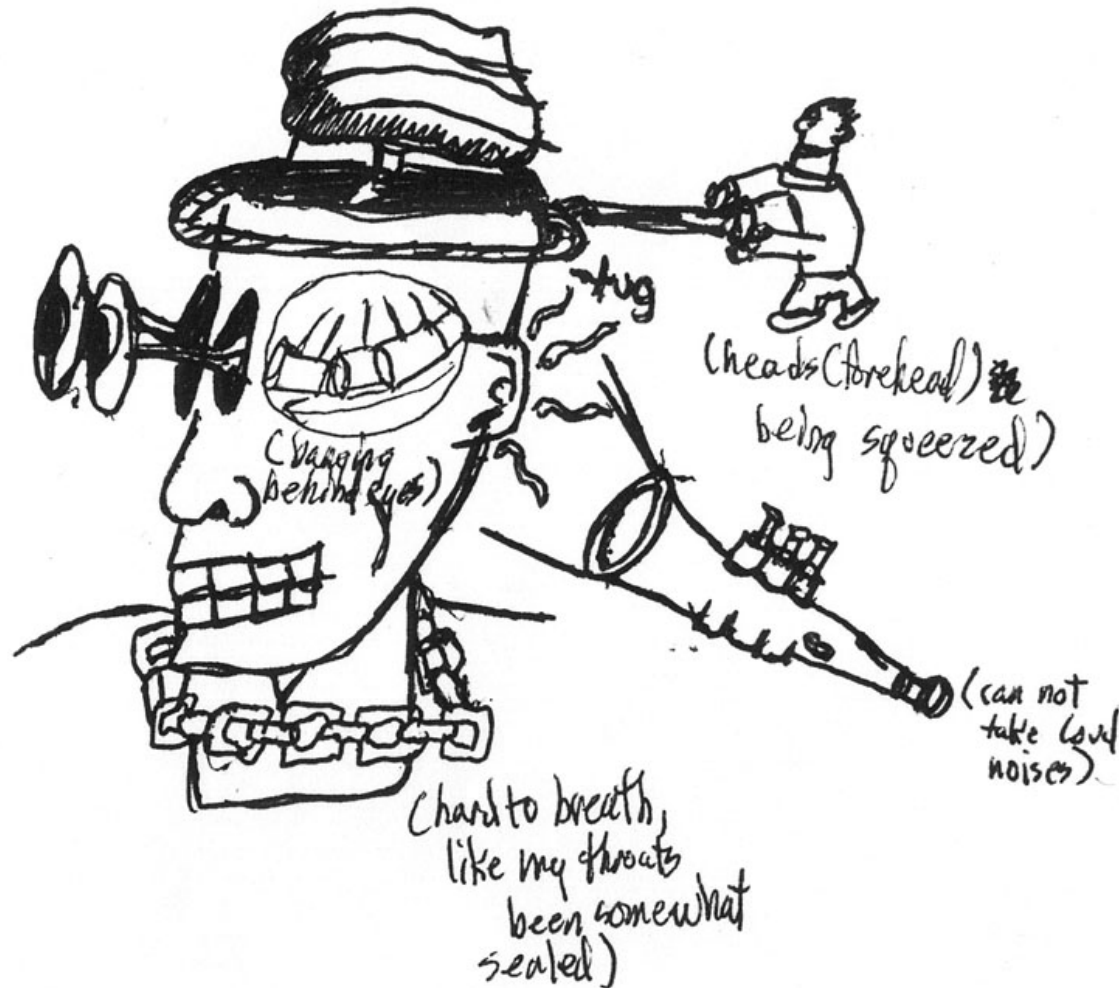


CUTANEOUS ALLODYNIA

1. Peripheral Trigeminal Sensitization
2. Central Trigeminal Sensitization
Forehead Allodynia
3. Thalamic Sensitization
Extracephalic allodynia

MIGRAINE

The Worst Headache EVER!! ~ ~



CLINICAL RESPONSE TO SUBCUTANEOUS SUMATRIPTAN IN A CLINICAL SETTING

Sumatriptan – Subcutaneous 0.06 mg/kg ^{Linder}
(overall efficacy 78%)

Males – 91%

Females – 68%

RESPONSE TIME>

Headache relief in 30 minutes	-	26%
Headache relief in 60 minutes	-	46%
Headache relief in 2 hours	-	6%
No or sub-optimal relief	-	22%
Recurrence	-	6%

(only one responder had recurrence)

Adverse events with sumatriptan:

Atypical sensations

Ear, Nose & Throat Discomfort

Injection Site Reaction

Musculoskeletal pain and stiffness

Neurological

Dizziness/Vertigo	6%
Drowsiness/Sedation	8%
Headache increase	6%
Confusional state	2%
Post headache personality change	2%

DHE Protocol

Age	Metoclopramide (Oral)	DHE (IV)
6–9 yrs	5-10 mg/dose	0.1 mg/dose
9–12 yrs	5-10 mg/dose	0.15 mg/dose
12–16 yrs	5-10 mg/dose	0.2 mg/dose

For prolonged vascular headache, repeat oral metoclopramide and i.v. DHE every 6 hours for maximum of sixteen doses. When the headache ceases, give 1-2 additional dose.

The DHE dose may be increased by 0.05 mg/dose to the point where the patient has mild abdominal discomfort.

Antiemetic administered orally 30 min prior to the administration of i.v. DHE, maximum dose of metoclopramide is 10 mg. Normal dose 0.2-mg/kg. If extrapyramidal syndrome, give diphenhydramine hydrochloride, 1 mg/kg (maximum dose of 50 mg) and discontinue metoclopramide. For subsequent treatments administer ondansetron hydrochloride, 0.15 mg/kg i.v., 30 min prior to DHE dose. If significant myofascial component then use i.v. ketorolac 7.5–15 mg every 6 hours alternating with DHE.

DHE HIGHLIGHTS

1. Use oral metoclopramide to avoid EPS
2. Start with low dose of DHE and give every six hours
3. Infuse DHE over 1 hour with 50 cc of normal saline
4. If myofascial tenderness or signs of central allodynia, use ketorolac
5. Patient should be started on an anti-migraine regimen

Adverse Experiences Associated with DHE Treatment at Cincinnati Children's Hospital

Nausea/Vomiting	91.4%
Chest Tightness	6%
Hives	2.8%
Face flushed	2.8%
Increased blood pressure	2.8%
IV site discomfort	97.3%
No side effects	8.6%

Raskin's DHE Protocol

DHE dose was 0.5 mg – 1 mg given IV push every 8 hours

This protocol can activate the receptors that the medicines are trying to suppress!

Children, in general, do not tolerate these higher doses unless escalated slowly

Proposed Headache ER Protocol

If headache is compatible with migraine and the patient does not have cutaneous allodynia, then utilize subcutaneous sumatriptan 0.06mg/kg (maximum 6 mg)

If patient has cutaneous allodynia then best to proceed to DHE protocol

DHE Protocol

1. 20 cc/kg (maximum of 1000 cc) of D5 ½ normal saline & KCL 20 mcq/1000 cc) over 1-2 hours
2. Ketorolac 0.4 mg/kg (maximum 30-mg) + prochlorperazine 0.15 mg/kg (maximum 10-mg) IV
3. 30 minutes later start ondansetron 0.15 mg/kg IV (maximum 8-mg)
4. Wait 15-30 minutes then start –dihydroergotamine IV
0.2 mg in 100 cc normal saline (ages 9-13)
0.3 mg in 100 cc normal saline (ages 14-17)
administered over 1 hour
5. If no improvement in 60 minutes or if extrapyramidal side effects give diphenhydramine 1-mg/kg (maximum 50-mg), and discharge

Alternative to DHE

- Divalproex sodium IV 15-20 mg over 5 minutes maximum dose 1 gram
have been proposed for the near future

CASE HISTORY

Ten year old male with history of migraine since 7 years of age, well controlled on cyproheptadine daily with the use of Excedrin for acute headache. Over the past month the headaches have become more frequent and severe. The patient was hit in the head with a baseball bat 4 days prior to admission with a constant headache since that time. Seen in the emergency room with a non-focal examination, weight 40 kg. CT was normal. Was give sumatriptan 6-mg SQ with an increase in headache pain. Was then given promethazine and meperidine and he went to sleep.

The next day the headache returned and he was seen in the ER. Comprehensive headache examination showed bilateral supraorbital nerve tenderness, bilateral temporalis tenderness as well as tenderness in the neck. He was treated with IV metoclopramide followed by dihydroergotamine 45-0.5 mg IV. He had exacerbation of his headache plus became extremely restless. He was admitted to the hospital for further evaluation.

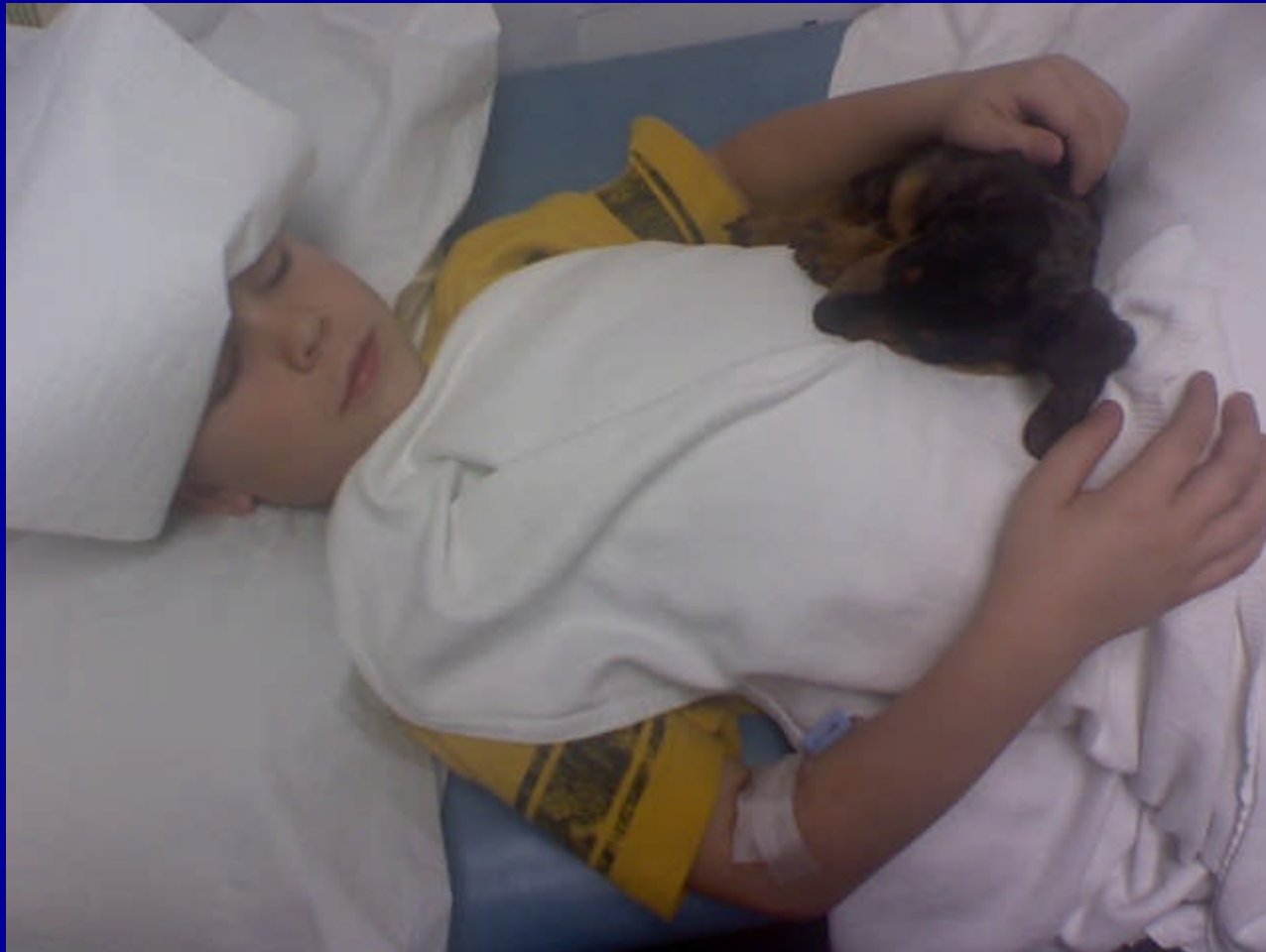Case Study

- 8 year old male on triptan protocol developed headache after using the medicine. No medicines can be used.

How do you treat?

Dexter Therapy

Dexter Therapy (ice pack and a sleepy puppy)



Post Dexter Therapy
Time to headache relief
– 10 minutes !



Thank You

